

# Trigeminal and occipital peripheral nerve stimulation for craniofacial pain: a single-institution experience and review of the literature

KONSTANTIN V. SLAVIN, M.D., M. EFKAN COLPAN, M.D., NAUREEN MUNAWAR, M.D., CHRISTIAN WESS, M.D., AND HRACHYA NERSESYAN, M.D., PH.D.

*Department of Neurosurgery, University of Illinois, Chicago, Illinois*

**Object.** Treatment of chronic neuropathic pain in the region of the head and face presents a challenge for pain specialists; patients who do not respond to conventional treatment modalities usually continue to suffer from pain due to the lack of reliable medical and surgical approaches. Peripheral nerve stimulation (PNS) has been used to treat neuropathic pain for many decades, but only recently has it been applied systematically to the craniofacial region. To advance the study of this treatment option, the authors present their initial experience with this approach, summarize published data on the use of PNS in treatment of craniofacial pain, and discuss some technical details of the craniofacial PNS procedure.

**Methods.** A review of prospectively collected data in 30 patients who underwent PNS surgery for craniofacial pain was performed. The pain location, duration, cause, and previous treatments were analyzed, along with the surgical details, initial and long-term results, complications, and repeated operations.

Stimulated nerves in this group included supraorbital (seven patients), infraorbital (six), and occipital (21); in 19 patients more than one nerve was stimulated. Twenty-two patients proceeded with implantation of a permanent system after the trial. Of these, at the time of the latest evaluation (mean follow-up duration 35 months), in two patients the devices had been removed because of pain improvement over time, in three the devices were removed due to loss of effectiveness (two cases) or late infection (one), and the rest are enjoying either complete (15 patients) or partial (two patients) pain relief. Three patients underwent repeated operation due to lead erosion, infection, or migration.

**Conclusions.** Peripheral nerve stimulation appears to be a safe and effective approach in the treatment of craniofacial neuropathic pain. The growing body of literature supports a wider acceptance of this approach in the field of pain surgery.

**KEY WORDS** • pain • neuromodulation • peripheral nerve stimulation • occipital nerve stimulation • trigeminal nerve

THE idea of using PNS to treat craniofacial pain is not new. The interest in this modality has been increasing over the last few years, but the original applications date back to the 1960s. When Wall and Sweet<sup>19</sup> tried to find a new approach to suppress neuropathic pain, they inserted an electrode into their own infraorbital foramina and obtained a decrease in pain perception during the entire episode of electrical stimulation.<sup>23</sup> Moreover, in the first article dedicated to the idea of PNS with implantable devices (even before spinal cord stimulation was introduced),<sup>19</sup> one of the eight patients with neuropathic pain presented with severe facial pain, and in this patient an electrode was inserted deep into the infraorbital foramen. The stimulation resulted in lasting pain suppression as long as the stimulator was on. Later, in another patient a system was applied to the temporal area, delivering stimulation aimed at the branches of the mandibular nerve.<sup>23</sup> At approximately the same time, Shel-

den<sup>12</sup> implanted electrodes wrapped around the mandibular nerve itself in three patients and stimulated the nerves through an implanted receiver at 14,000 Hz, thus achieving temporary pain relief.

The use of PNS for craniofacial neuropathic pain was rediscovered in 1999 with the publication of an article by Weiner and Reed<sup>22</sup> in which they described percutaneous electrode insertion in the vicinity of the occipital nerves. Soon after publication of that pioneering paper, we began using the PNS approach in both the occipital and trigeminal regions.<sup>13,14</sup> Many other publications detailing the experience in many centers and describing different PNS techniques and applications have appeared over the last several years.<sup>1-11,15-17,20,21</sup>

## Clinical Material and Methods

### Patient Population

We analyzed prospectively collected data in all patients who had undergone PNS for craniofacial pain in our insti-

*Abbreviations used in this paper:* PNS = peripheral nerve stimulation.

tution since 2000. The basic demographic characteristics, details of the patients' conditions, surgical aspects, and follow-up observations were summarized and reviewed. The small size of the group (41 patients) and its heterogeneity did not allow statistical analysis; therefore we limited our review to clinical outcomes and complications.

All 41 patients presenting with neuropathic pain in the face and/or head underwent diagnostic nerve blocks to establish participation of certain nerves in generation of the pain. Of these patients, 30 were considered candidates for PNS surgery. They were sent for routine neuropsychological testing and then underwent the stimulation trial. Demographic characteristics and pain parameters are summarized in Table 1.

#### *Surgical Technique*

The electrodes are inserted for the trial in a sterile fashion, either after the induction of local anesthesia or after sedation augmented by infiltration of the insertion site with local anesthetic. Because the procedure is brief and the surgical site is quite superficial, general anesthesia is almost never needed.

The direction of electrode insertion may be chosen based on the surgeon's preference: we routinely insert electrodes from lateral to medial, not only in the supraorbital and infraorbital regions (where it is probably the only way to place them),<sup>17</sup> but also in the occipital area,<sup>15</sup> as opposed to some other centers in which insertion of electrodes from medial to lateral is preferred.<sup>1,10</sup> Standard four- or eight-contact electrodes were used (Fig. 1); the electrodes were passed in the epifascial plane under the skin but above the muscles. Our general approach is to have the electrode cross the path of the nerve chosen as a stimulation target. As long as this nerve happens to be either under one of the electrode's contacts or between two contacts, the stimulation can be steered toward it to get adequate coverage. For the trial insertion, we did not implant any deep anchors or extensions; the electrodes were sutured to the skin with plastic anchors and fine nylon, and a strain-relief loop was created around the insertion site to avoid inadvertent electrode pullout.

The electrodes were inserted using fluoroscopic guidance. Standard landmarks were used for the insertion: the supraorbital groove or foramen and the supraorbital ridge for the supraorbital nerve; the infraorbital foramen and the floor of the orbit for the infraorbital nerve; and the C-1 arch and radiographic midline for the occipital nerves. In

TABLE 1

*Demographic characteristics of patients selected for PNS trial*

Characteristic	Value
sex	
female	22
male	8
age (yrs)	47.3 (range 22–97)
duration of pain	4 yrs (range 8 mos–12 yrs)
location of pain (no. of patients)*	
lt supraorbital	5
rt supraorbital	4
lt infraorbital	1
rt infraorbital	5
lt occipital	16
rt occipital	18
causative factors (no. of patients)	
trigeminal op	3
Chiari decompression	3
other ops	8
trauma	5
rheumatoid arthritis	1
unknown	10
duration of trial (days)	6 (range 4–7)

\*Pain was noted in more than one territory in 19 patients.

the beginning, we tested each patient for stimulation-induced paresthesias in the operating room so that the position of the electrode could be adjusted if needed. Lately, however, we have been relying exclusively on anatomical electrode positioning due to its high reliability in getting appropriate coverage. This has resulted in significant improvement in the patient's comfort associated with the deeper sedation, which may now be used because the patient's cooperation during the procedure is not needed. The electrode is covered with sterile dressing and attached to the external stimulation system; the initial programming is performed to produce adequate paresthesias in the painful area; the patient is instructed on adjustment of the stimulator depending on activity and pain level; and antibiotics are prescribed for the duration of the trial to avoid development of superficial infection (although the need for this particular step is not supported by any clinical evidence).

Once the trial is completed, the temporary system is replaced with the permanent one. We prefer to remove the temporary electrode and then insert a new permanent electrode that is connected either directly to the generator or to

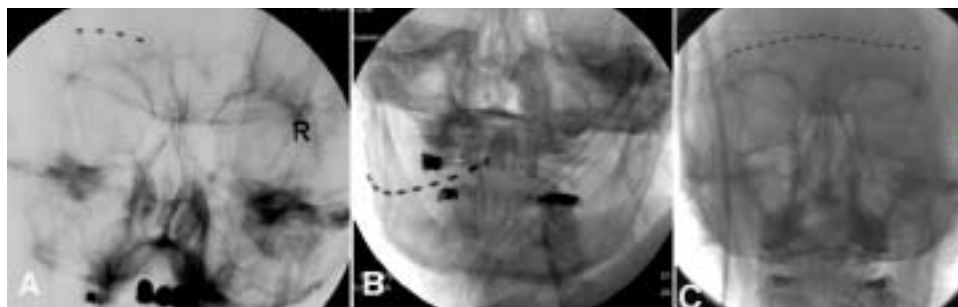


FIG. 1. Radiographs showing positioning of electrodes. A: Unilateral four-contact supraorbital nerve stimulation electrode. B: Unilateral eight-contact occipital nerve stimulation electrode. C: Bilateral eight-contact supraorbital nerve stimulation electrodes.

## Peripheral neuromodulation for craniofacial pain

an extension cable that connects to the generator. The electrodes we use are cylindrical “wire” types (such as Quad, Octad, Quad Plus, or Quad Compact [Medtronic, Inc.]; Qattrode, Octrode, or Axxess [Advanced Neuro-modulation Systems]; and Linear [Advanced Bionics]). The electrodes or extension cables are tunneled toward the generator pocket. The tunneling step is quite painful and necessitates the use of general anesthesia. Location of the pocket is chosen based on the patient’s and surgeon’s preference. We routinely use the infraclavicular area for both trigeminal and occipital nerve stimulation systems, and in this way the procedure is similar to the one used for placement of deep brain stimulation generators. (According to our recent survey,<sup>18</sup> the patients with infraclavicular generators were found to have a very high level of satisfaction with this particular location.) The pocket should satisfy certain requirements: 1) it has to be deep enough to avoid hardware erosion; 2) it should not be too deep, thus interfering with reprogramming or, in the case of rechargeable devices, their regular charging; and 3) it should be located in a relatively immobile region because the hardware may fail if subjected to repetitive mechanical stress.

### Results

Of 30 patients who underwent the trial stimulation, only 22 (73%) experienced more than a 50% reduction in pain intensity and went on to have a permanent system implanted. Among these patients, three had infraorbital PNS, four had supraorbital, in 13 it was occipital, and one each had a combination of infraorbital and occipital or supraorbital and occipital stimulation. Twelve patients had bilateral stimulation (10 occipital and two supraorbital). A total of 36 electrodes and 22 generators were implanted in this series.

Complications directly related to the implant surgery occurred in two cases; in one patient problems were found with the connection between the generator and the extension cable, necessitating a return to the operating room and revision of the PNS system on the same day as internalization, and in another electrode migration developed that required a repeat of the operation 2 weeks later. There were no infections in the immediate postoperative period; no patient developed problems with the generator pocket site.

The patients underwent periodic follow-up evaluations for a mean of 35 months after the implant (range 1–77 months; 18 patients were followed for > 1 year, and 13 for > 3 years). By the time of the latest follow-up visit, the systems had been removed in five patients. In two of them the reason for PNS system removal was improvement in pain intensity; both patients stopped using their stimulator at least 6 months prior to its removal. In two other patients the initial benefit of stimulation was lost after 2 years in one and 6 months in the other. Both of them continued to experience pain despite reprogramming attempts, and their devices were removed soon thereafter. In the fifth patient the system was removed because an infection developed in the generator pocket 2 years after implantation; this complication was most likely due to hematogenous spread following bacteremia.

Of the 17 patients who continue to use the PNS device for pain control, three have stated that PNS improves their

pain by less than 50% of its intensity (partial responders), whereas 14 have reported more than 50% improvement in pain intensity based on the visual analog scale (responders). Three patients required a repeat of the operation during the follow-up period. In one patient skin erosion developed over the electrode tip; his electrode was removed and then reimplanted 1 month later, with complete return of stimulation benefits. In another patient an infection developed over the connector between the electrode and the extension cable. This problem was solved by removing the electrode/extension cable and reinserting it 3 months later, after antibiotics were used to treat the infection. The benefits of stimulation were restored after the system was reimplanted. In the third patient, the workup for loss of the stimulation benefits revealed migration of the electrode, which was corrected in a repeated operation.

Altogether, of 22 patients in whom PNS devices were implanted for craniofacial pain, 16 (73%) experienced significant (> 50%) improvement in pain intensity (14 with and two without stimulation); three patients (13.5%) reported less than 50% pain improvement; and three (13.5%) continued to experience pain after their devices were removed due to either loss of effect or infection. The percentage of successful outcomes decreases if one takes into consideration all patients who were candidates for the trial (16 [53%] of 30) or those who presented with pain and underwent nerve blocks with local anesthetic (16 [39%] of 41), even though there was some possibility of pain improvement without stimulation among those who did not undergo PNS surgery.

### Discussion

#### *Indications for PNS*

General indications for PNS are quite specific: it is usually recommended for patients with neuropathic pain of various origins as long as there is some preservation of sensation in the painful area. The four most common indications applicable to the craniofacial region that have been described in the literature are as follows: 1) postherpetic neuralgia involving the territory of the trigeminal nerve; 2) posttraumatic or postsurgical neuropathic pain that is related to an underlying dysfunction of the infraorbital, supraorbital, or occipital nerve; 3) “transformed migraine” presenting with occipital pain and discomfort; and 4) occipital neuralgia or cervicogenic occipital pain. In each of these situations, the patients have anatomical distribution of pain; their pain is medically intractable; they had favorable results on neuropsychological testing; the area of pain is not anesthetic (although hypesthesia and hyperesthesia are allowed); and, in the first two groups, the onset of pain is linked to a known traumatic, surgical, or infectious event. In most centers, a local anesthetic block is used to confirm involvement of the specific nerve in the generation of pain, although elimination of pain with a nerve block does not necessarily predict success of PNS. Therefore, a trial stimulation is performed to check responsiveness of the pain to the stimulation approach prior to implantation of the permanent system. Usually, a 50% improvement in pain intensity serves as a cutoff limit for considering the trial successful.

The psychological evaluation is routinely performed, at

least in our practice, where it has become a part of the evaluation of all patients who are considered for pain-relieving surgery. Prior to the intervention, early detection of somatization, untreated depression, drug abuse, and drug seeking as well as various secondary gains (not necessarily financial) that may not be obvious to the surgical team helps to predict the success of surgery and address the issues that may negatively affect the outcome.

The nerves that are most frequently selected for stimulation are supraorbital, infraorbital, and, less often, auriculotemporal and supratrochlear in cases of facial pain, and greater and lesser occipital nerves in cases of occipital pain. In our opinion, stimulating the nerve itself may be more effective than field stimulation, but this is debatable because the surgeons who prefer field stimulation achieve very similar clinical results in terms of improvement and overall success.

### *Surgical Procedure*

We used only wire-type (percutaneous) electrodes for both trigeminal and occipital stimulation.<sup>15-17</sup> Other groups reported using plate-type (also called paddle-type) electrodes (Resume, Resume II, or Resume TL; Medtronic, Inc.) for stimulation of occipital nerves. Implantation of such electrodes can be preceded by a trial with wire-type electrodes,<sup>5</sup> or the trial can be done with a plate-type electrode connected to a temporary extension.<sup>9</sup> In all cases the electrodes are placed over the path of the peripheral nerve that supplies the painful area and may be involved in the generation of pain.

The generator pocket in our series was always created in the infraclavicular region.<sup>18</sup> Placement of generators in the gluteal area,<sup>5,11</sup> abdominal wall,<sup>3,22</sup> or infraclavicular areas<sup>4,9,22</sup> has been described.

### *Treatment Results*

According to our review of the literature, all published reports on the use of PNS for control of neuropathic craniofacial pain have shown significant and lasting improvement in pain intensity. What follows is a brief review of published experience based on the diagnosis of the condition being treated, although one has to keep in mind that labeling painful conditions may be difficult at times.

The largest group of patients who underwent PNS suffered from occipital neuralgia and cervicogenic headaches. Pain in these patients' was located primarily in the occipital region and the upper part of the neck, sometimes radiating toward the vertex or even the forehead. The participation of the occipital nerves in these pain syndromes was usually confirmed by results of local anesthetic blocks of the greater and lesser occipital nerves. Weiner and Reed<sup>22</sup> in 1999 reported improvement in all 13 patients with unilateral or bilateral occipital neuralgia who underwent occipital PNS implantation, and whose mean follow-up duration was 2 years. Later, the same authors reported 80% success in a group of 62 patients with intractable occipital headaches.<sup>21</sup> Hammer and Doleys<sup>3</sup> presented a report on a patient with occipital neuralgia who underwent implantation with an obliquely placed eight-contact electrode; she maintained 90% improvement in pain intensity as well as improvement in most psycholog-

ical indicators. Oh et al.<sup>9</sup> described excellent and good outcomes at the 1-month follow-up interval in all 10 of their patients with occipital neuralgia (> 75% pain relief), and that effect persisted in eight of 10 at the 6-month follow-up visit. Rodrigo-Royo et al.<sup>11</sup> reported on three patients with occipital pain and headaches and one with postherpetic occipital pain; all of them improved after receiving occipital PNS, and this improvement persisted until their last follow-up visit 4 to 16 months postimplantation.

In a series of patients with occipital neuralgia reported by Nörenberg and Winkenmüller,<sup>8</sup> three candidates proceeded with the permanent implantation after the trial, whereas two others did not benefit from stimulation, presumably due to preexisting impairment of sensation in the painful region. In a pilot study by Kapural et al.,<sup>5</sup> six patients with occipital neuralgia who underwent implantation of paddle-type electrodes maintained significant improvement at the 3-month follow-up visit. In our current series, in a group of 18 patients with occipital neuralgia, 13 exhibited improvement of pain during the trial and underwent implantation of the permanent system. Over the mean follow-up period of 28 months, the beneficial effect of long-term occipital PNS persisted in 85% of those who significantly improved during the trial.

Another indication for occipital PNS that is currently being investigated is so-called transformed migraine. Migraine is a very common affliction, and sometimes it is medically intractable. Recently, pain specialists started linking occipital neuralgia with "spinally transformed migraine," sometimes using these terms interchangeably.<sup>1</sup> Popeney and Aló<sup>10</sup> reported results of occipital PNS in 25 patients with chronic disabling transformed migraine; at a mean follow-up interval of 18 months, improvement in the migraine disability assessment score was almost 90%. All 10 patients with severe chronic migraine who were evaluated using positron emission tomography studies by Matharu et al.<sup>7</sup> achieved excellent pain relief with suboccipital stimulators (although one patient also required bilateral supraorbital stimulation). Whereas percutaneous, wire-type electrodes were used in these two studies, Oh et al.<sup>9</sup> reported on 10 patients with transformed migraines who underwent implantation of paddle-type electrodes (seven of them initially had received percutaneous electrodes that migrated and were replaced with surgical leads); all 10 had more than 75% pain relief at both 1 and 6 months after the implantation.

Indications for PNS of the trigeminal branches are limited primarily to trigeminal neuropathic pain and postherpetic neuralgia. In one case, supraorbital stimulation was used in addition to bilateral occipital PNS for treatment of chronic migraine.<sup>7</sup> Treatment of postherpetic neuralgia involving the ophthalmic nerve distribution by using the PNS technique was first described by Duntzman<sup>2</sup> in 2002; two patients received unilateral supraorbital PNS implants and maintained excellent pain relief for 3 years. Recently, Johnson and Burchiel<sup>4</sup> reported their results in four patients with postherpetic neuralgia affecting the supraorbital region; two of these patients maintained more than 50% pain relief after 2 years of follow up.

In regard to posttraumatic or postsurgical neuropathic trigeminal pain, Slavin and Burchiel<sup>13,14</sup> reported more than 50% improvement in pain intensity in all patients who had

undergone permanent implantation of a PNS system since 1998. In a group of six of these patients, one failed to improve during the trial, and the remaining five maintained significant (> 50%) improvement in pain, with a mean follow-up duration of longer than 26 months.<sup>4</sup> We observed somewhat similar results; nine of 12 patients proceeded with implantation of a permanent PNS system, and in three the system was subsequently removed for the following reasons: improvement of pain, the loss of efficacy, and a generator site infection (one each). Five of the remaining six patients maintained more than 50% pain improvement over a mean of 44 months of follow up. In Johnson and Burchiel's<sup>4</sup> experience, of six patients with nonherpetic trigeminal neuropathic pain, supraorbital and infraorbital distribution of pain was observed in three patients each. In our cohort, four patients had unilateral infraorbital pain; two each had unilateral supraorbital, bilateral supraorbital, and unilateral supraorbital and occipital pain; and of the two remaining patients, one had unilateral infra- and supraorbital and the other had unilateral infraorbital and occipital pain.

The overall rate of complications in the literature and in our series was low; the majority of complications (wound breakdown, skin erosion, focal infections, discomfort due to a short extension cable, and so on) were minor, and even if additional interventions were needed, none caused any serious or lasting problem.

### Conclusions

The number of centers using PNS for craniofacial pain is increasing, and as the experience grows one may expect better definitions of criteria predictive of lasting positive outcome. The appearance of larger clinical series will probably result in wider acceptance of this treatment approach, and its low invasiveness, testability, reversibility of effect, and the adjustability of settings may make it the preferred modality for otherwise intractable conditions.

### References

- Aló KM, Holsheimer J: New trends in neuromodulation for the management of neuropathic pain. **Neurosurgery** 50:690–704, 2002
- Duntzman E: Peripheral nerve stimulation for unremitting ophthalmic postherpetic neuralgia. **Neuromodulation** 5:32–37, 2002
- Hammer M, Doleys DM: Perineuromal stimulation in the treatment of occipital neuralgia: a case study. **Neuromodulation** 4:47–52, 2001
- Johnson MD, Burchiel KJ: Peripheral stimulation for treatment of trigeminal postherpetic neuralgia and trigeminal posttraumatic neuropathic pain: a pilot study. **Neurosurgery** 55:135–142, 2004
- Kapural L, Mekhail N, Hayek SM, Stanton-Hicks M, Malak O: Occipital nerve electrical stimulation via the midline approach and subcutaneous surgical leads for treatment of severe occipital neuralgia: a pilot study. **Anesth Analg** 101:171–174, 2005
- Lou L: Uncommon areas of electrical stimulation. **Curr Rev Pain** 4:407–412, 2000
- Matharu MS, Bartsch I, Ward N, Frackowiak RSJ, Weiner R, Goadsby PJ: Central neuromodulation in chronic migraine patients with suboccipital stimulators: a PET study. **Brain** 127:220–230, 2004
- Nörenberg E, Winkel Müller W: [The epifacial electric stimulation of the occipital nerve in cases of therapy-resistant neuralgia of the occipital nerve.] **Schmerz** 15:197–199, 2001 (Ger)
- Oh MY, Ortega J, Bellotte JB, Whiting DM, Aló K: Peripheral nerve stimulation for the treatment of occipital neuralgia and transformed migraine using a C1–2–3 subcutaneous paddle style electrode: a technical report. **Neuromodulation** 7:103–112, 2004
- Popeney CA, Aló KM: Peripheral neurostimulation for the treatment of chronic, disabling transformed migraine. **Headache** 43:369–375, 2003
- Rodrigo-Royo MD, Azcona JM, Quero J, Lorente MC, Acín P, Azcona J: Peripheral neurostimulation in the management of cervicogenic headaches: four case reports. **Neuromodulation** 8:241–248, 2005
- Shelden CH: Depolarization in the treatment of trigeminal neuralgia. Evaluation of compression and electrical methods; clinical concept of neurophysiological mechanism, in Knighton RS, Dumke PR (eds): **Pain**. Boston: Little, Brown, 1966, pp 373–386
- Slavin KV, Burchiel KJ: Peripheral nerve stimulation for painful nerve injuries. **Contemp Neurosurg** 21(19):1–6, 1999
- Slavin KV, Burchiel KJ: Use of long-term nerve stimulation with implanted electrodes in the treatment of intractable craniofacial pain. **J Neurosurg** 92:576, 2000 (Abstract #827)
- Slavin KV, Nersesyan H, Wess C: Peripheral neurostimulation for treatment of intractable occipital neuralgia. **Neurosurgery** 58:112–119, 2006
- Slavin KV, Nersesyan H, Wess C: Treatment of neuropathic craniofacial pain using peripheral nerve stimulation approach, in Meglio M, Krames ES (eds): **Proceedings of 7th Meeting of International Neuromodulation Society, Rome, Italy, June 10–13, 2005**. Bologna: Medimond, 2005, pp 77–80
- Slavin KV, Wess C: Trigeminal branch stimulation for intractable neuropathic pain: technical note. **Neuromodulation** 8:7–13, 2005
- Syed M, Slavin KV: Infraclavicular generator placement for neurostimulation: are the patients satisfied? in Meglio M, Krames ES (eds): **Proceedings of 7th Meeting of International Neuromodulation Society, Rome, Italy, June 10–13, 2005**. Bologna: Medimond, 2005, pp 81–84
- Wall PD, Sweet WH: Temporary abolition of pain in man. **Science** 155:108–109, 1967
- Weiner RL: Peripheral nerve neurostimulation. **Neurosurg Clin N Am** 14:401–408, 2003
- Weiner RL, Aló KM, Reed KL, Fuller ML: Subcutaneous neurostimulation for intractable C-2-mediated headaches. **J Neurosurg** 94:398A, 2001 (Abstract)
- Weiner RL, Reed KL: Peripheral neurostimulation for control of intractable occipital neuralgia. **Neuromodulation** 2:217–221, 1999
- White JC, Sweet WH: **Pain and the Neurosurgeon. A Forty-Year Experience**. Springfield, IL: Charles C. Thomas, 1969, pp 894–899

Manuscript received September 13, 2006.

Accepted in final form October 25, 2006.

Address reprint requests to: Konstantin Slavin, M.D., Department of Neurosurgery, M/C 799, 912 South Wood Street, Chicago, Illinois, 60612. email: kslavin@uic.edu.